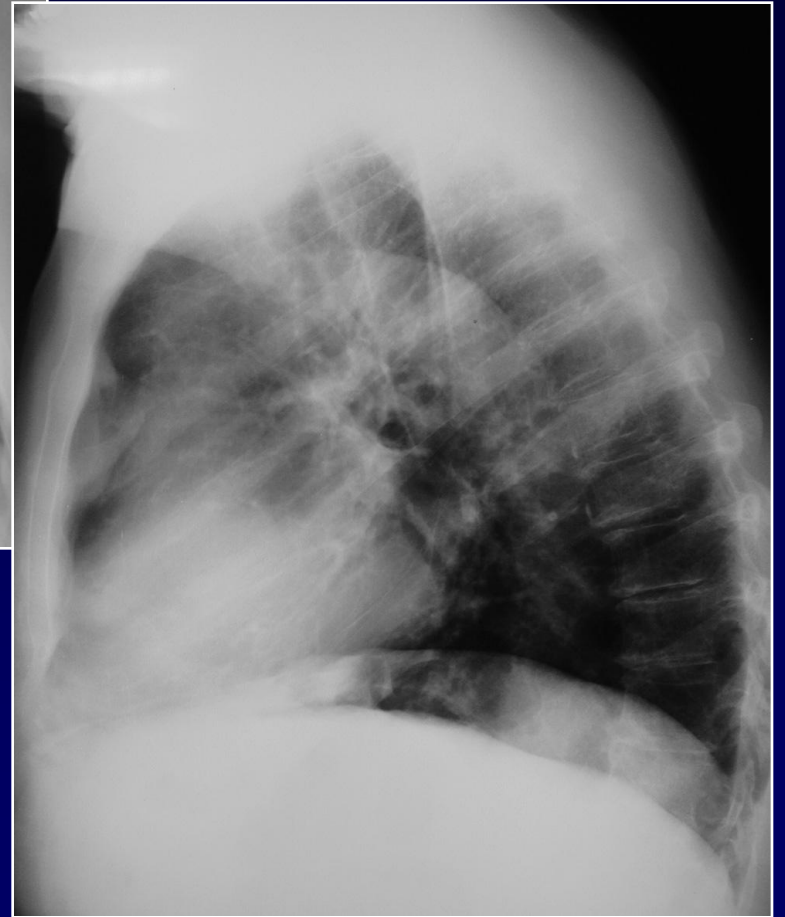
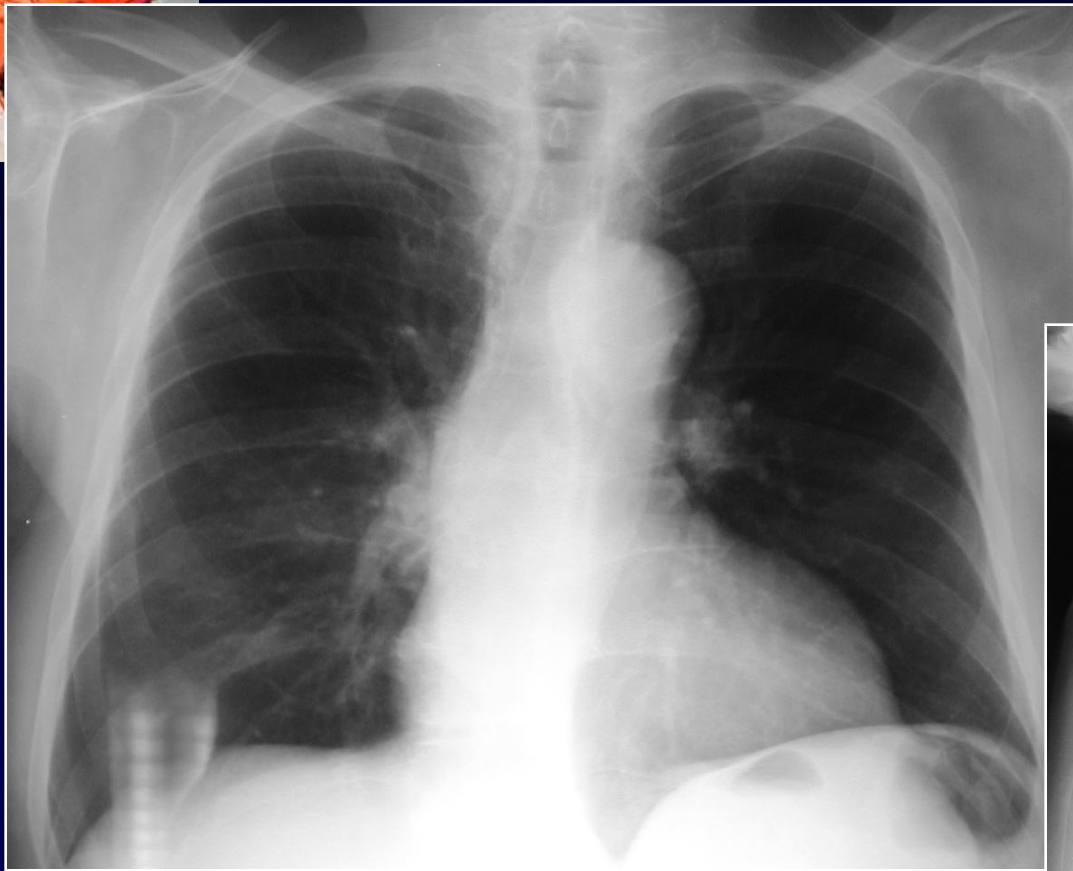



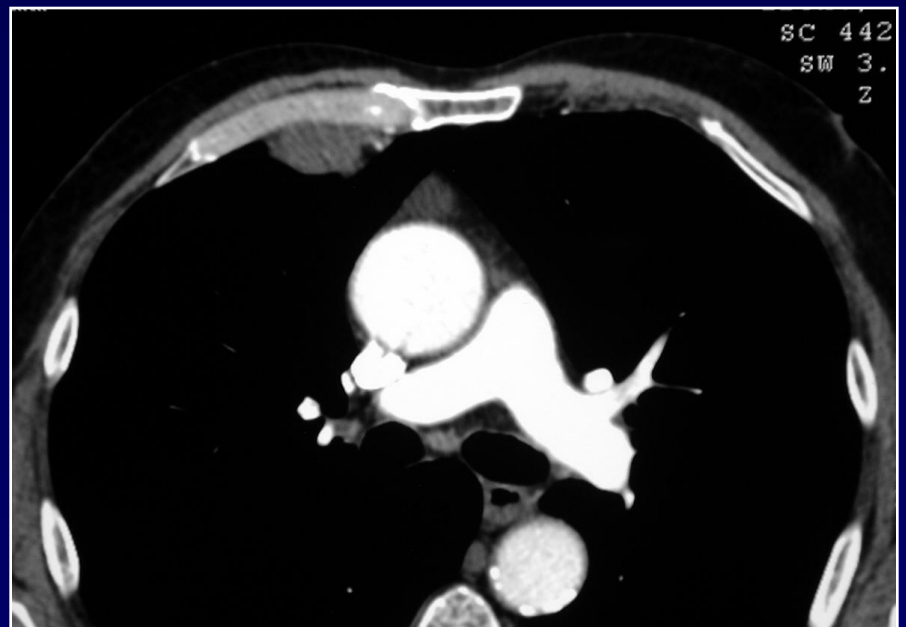
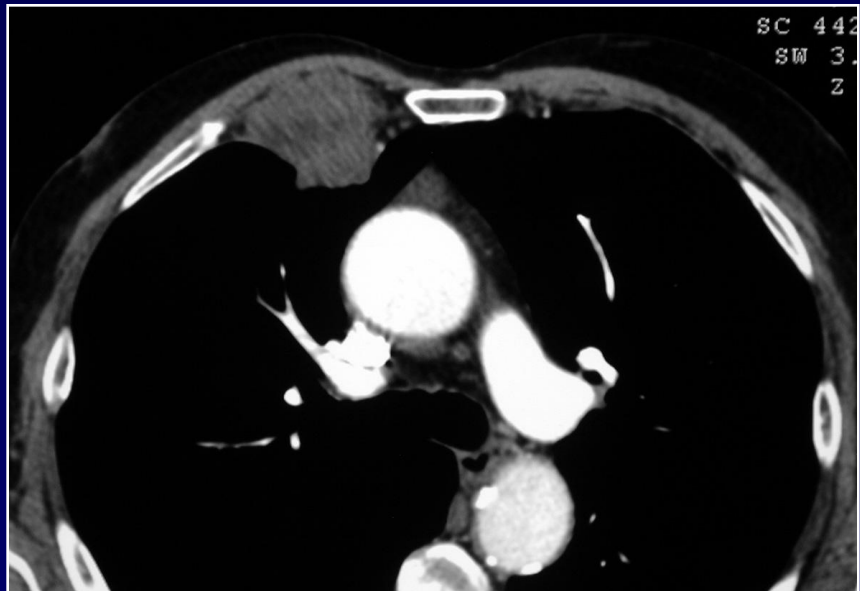
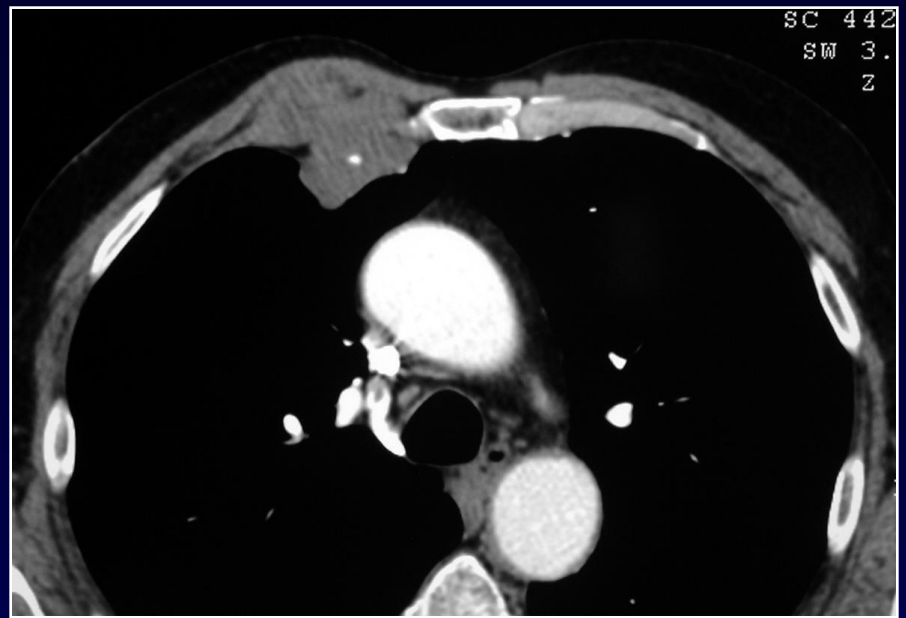
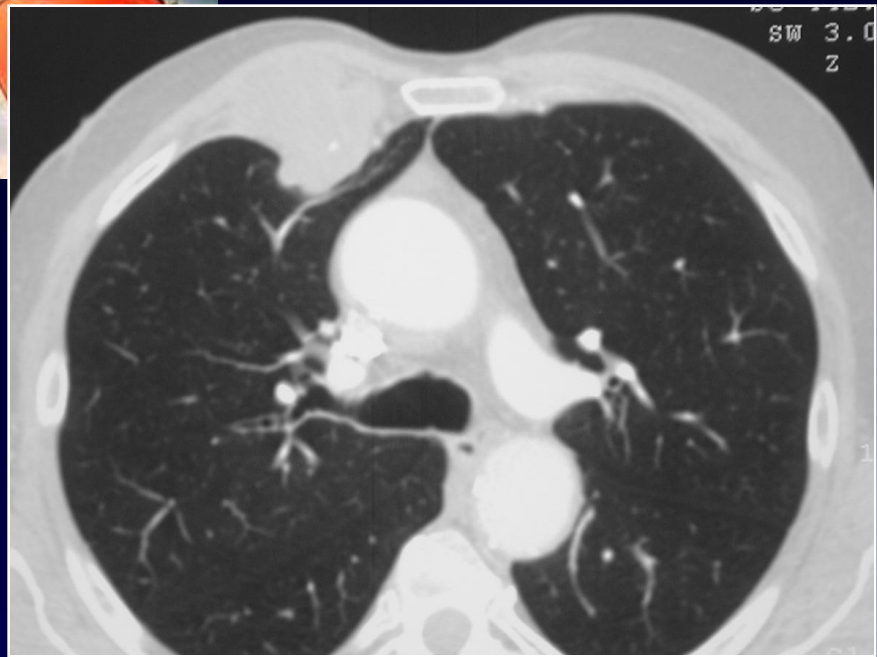
**P FAJADET**

**Homme de 71 ans**

**Douleurs thoraciques**



**Radiographie thoracique**





**Diagnostic ?**



# Chondrosarcome pariétal

Diagnostic par biopsie